

Research Journal of Pharmaceutical, Biological and Chemical Sciences

An Ectopic Pregnancy with Atypical Presentation.

K Lavanya*¹, K Saraswathi² and SM Priyadharshini³.

Department of Obstetrics and Gynaecology, Sree Balaji Medical College and Hospital, Bharath University, Chennai, Tamil Nadu, India.

ABSTRACT

Ectopic pregnancy is defined as implantation of a fertilized ovum outside the uterine cavity. This is an unusual case of ectopic pregnancy. A 29 year old woman reported to the clinic with continuous bleeding for 28 days, associated with pain on and off. There was no preceding amenorrhea with regular cycles. Clinically patient haemodynamically stable. The abdomen was soft, cystic to firm mass of about 7x6cm felt in suprapubic region more towards left iliac fossa, with restricted mobility, with negative serum beta human chorionic gonadotropin. Ultrasound revealed left ovarian mass. Laparotomy-left salpingectomy done and histopathology confirmed chronic ectopic pregnancy. Chronic ectopic pregnancy is difficult to diagnose in absence of classical symptoms.

Keywords: Chronic ectopic, Ovarianmass, Laparatomy.

**Corresponding author*

INTRODUCTION

Ectopic Pregnancy, implantation occupies at a site other than the endometrium. Various factors contribute to ectopic pregnancies, the most common being infection. Chronic ectopic pregnancies present a management quandary because the significance of the associated declining serum β -HCG levels is difficult to determine. It rarely presents as an ovarian mass without acute symptoms as in our case.

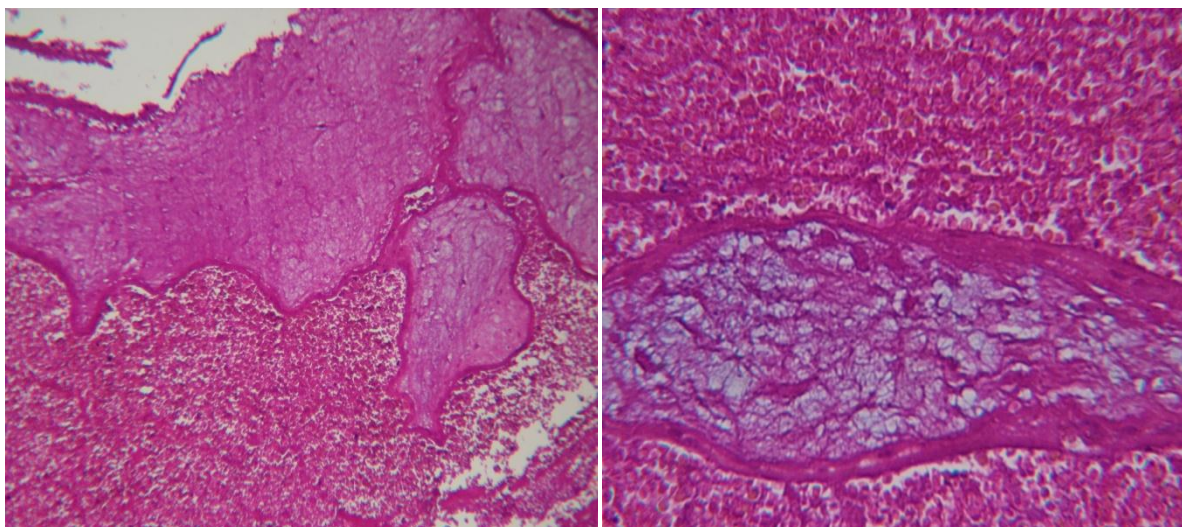
CASE REPORT

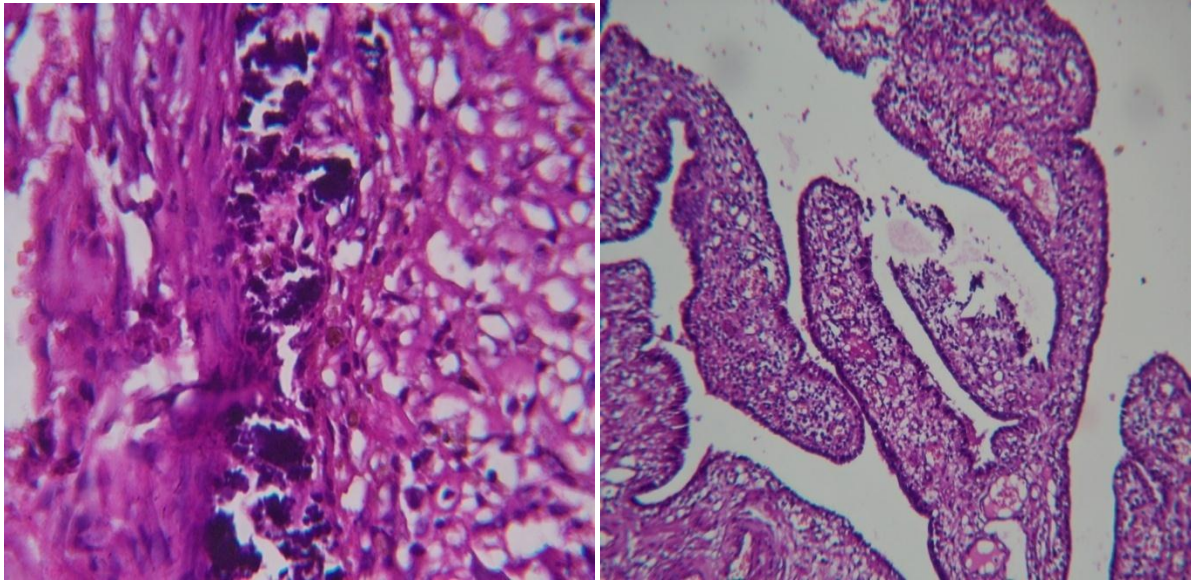
A 29 Year old woman was admitted with continuous bleeding for 28 days, not associated with clots, associated with pain on and off. H/O Changing one pad per day (FIRST EPISODE). There was no history of preceding amenorrhea. She was para 3 with death 3 who was delivered normally, All full term vaginal delivery with intrapartum eclampsia. All 3 still born fetus 6 yrs back. There were no menstrual irregularities. No previous history of pelvic infection. No history of contraceptive used. No other past illness.

On examination, patient was mildly anaemic, pulse rate-88 beats per min and blood pressure-120/80mmhg. Abdomen was scaphoid and soft on palpation, no guarding or rigidity, a cystic to firm mass of about 7x6 cm felt in suprapubic region more towards the left iliac fossa, mildly tender, with restricted mobility, borders palpable on all sides. On speculum examination revealed bleeding through os present, cervix and vagina healthy. On Bimanual examination revealed a Anteverted uterus, size bulky, cervix posterior, tense tender cystic mass of about 10x10cms felt in the left and posterior fornix with restricted mobility, other fornices free, cervical movement not painful.

On Investigations, haemoglobin-10.4gm/dl, urine pregnancy test-negative, serum β -HCG-3Miu/ml and other biochemical and hematological tests were normal. Ultrasonography of the pelvis revealed a left adnexa with multiloculated cystic mass lesion with septae and solid components measuring 10.6x4.3cm. Septae measuring 4mm, Solid components measuring 3.4x3.1cm, vascularity preserved. Uterus normal with Endometrial thickness-7mm and right ovary normal. Thin rim of free fluid noted in pouch of douglas, with Impression-*LEFT OVARIAN MASS*. To Consider-Dermoid cyst, cystadenoma of Left ovary. Hence CA-125-34IU/ml was done.

On Laparotomy, uterus was normal in size. Left tube elongated and dilated to about 6.5x5x3 cm which appeared like a hydrosalpinx, Left fimbria intact, blood clots present in the pouch of douglas with flimsy adhesions. Left ovary, Right tube and ovary were normal. Left Salpingectomy done. On cut section was haemorrhagic. On Microscopic examination, degenerated chorionic villi in a background of necrotic blood clot with occasional areas of calcification, Impression-*LEFT CHRONIC ECTOPIC PREGNANCY*





Pictures showing Left chronic Ectopic Pregnancy.

DISCUSSION

Ectopic pregnancy is the presence of gestational sac outside the endometrial cavity [1]. Approximately responsible for 10% of all maternal mortality. Nearly 95% of ectopic pregnancies are implanted in the various segment of the fallopian tube. Chronic ectopic pregnancy is a form of tubal pregnancy in which there is gradual disintegration of the tubal wall with slow or repeated episodes of hemorrhaging, which incites an inflammatory response often leading to the formation of a pelvic mass [2]. Haematoma formation, organization and reactive inflammatory changes and surrounding adhesions [2, 3, 5]. Haemodynamic stability, chronicity of symptoms and high incidence of false negative pregnancy tests are the characteristics of chronic ectopic pregnancy [3].

Risk factors are prior tubal damage-previous ectopic pregnancy, prior tubal surgery-Infertility/sterilization, use of Assisted Reproductive Technology, prior tubal infection or other sexually transmitted diseases. Peritubal adhesions, use of intrauterine devices. Symptoms-less severe abdominal pain, hemodynamic stability, Irregular bleeding pv during several weeks [4]. Chronic ectopic is an Distinct entity, diagnose may be difficult because normal anatomic landmarks are distorted by the formation of adhesions resulting from chronic inflammatory processes. A Definitive diagnosis is made only after surgery. Urine pregnancy test-negative due to absence of viable trophoblast. Serum β -HCG may be low or negative in chronic ectopic pregnancy mainly due to degeneration of trophoblast [4, 5]. Sonographically, the abnormality manifested by extrauterine, complex mass in the adnexae. The mass may obliterate the uterine margins and confused for adnexal mass [2]. TVS and Doppler are commonly used, In most ectopic pregnancy show no vascularity due to nonviable or involuting ectopic pregnancies [3].

The preferred mode of treatment is salpingectomy, either by laparoscopy or laparotomy. In present case report, the patient presented with pain abdomen and abnormal uterine bleeding and provisional diagnosis was left ovarian mass (dermoid cyst/cystadenoma of left ovary). Since patient was not affordable, treated with laparotomy and histopathology report confirmed as chronic ectopic pregnancy.

CONCLUSION

Chronic ectopic pregnancy can result from an undiagnosed ectopic pregnancy and it should be considered in the differential diagnosis of patients in reproductive age with persistent pelvic pain and a palpable adnexal mass, even with negative β -HCG and regular menstrual cycles.



REFERENCES

- [1] Nacharaju et al. Clinical Medicine Insights Reproductive Health 2014;8:1-4.
- [2] MJ Dickson et al. RCOG 2011:2.
- [3] Gulcinyildirim et al. Jeausobstet Gynecol 2014;1(3)46-48
- [4] Francois manson. 2006-03-28-16.Ectopic pregnancy with negative serum hcg level.
- [5] NB Levy et al. chronic ectopic pregnancy survey of 54 cases-SA MEDIESE TYDSKRIF DEEL 65 6 MEI 1984.
- [6] Poornima R Ranka et al. Ovariandermoid or chronic ectopic a diagnostic dilemma. 1999-4104-oct99.
- [7] Geetha et al. J Evol Med Dental Sci 2014;3(16): 4241-4244.